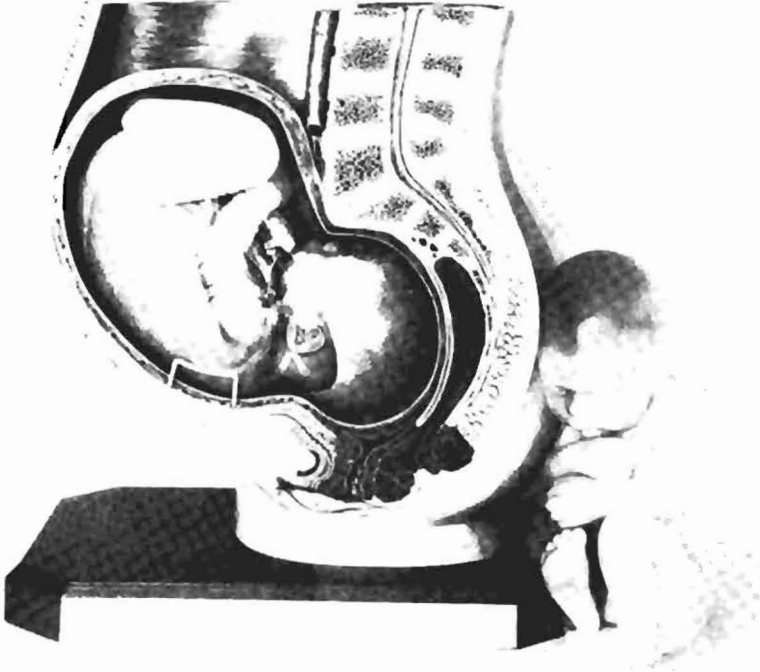


MD-18



MS 11, MS 12, MS 12/1-8,
MS 13, MS 13/1, MS 14



MS 13

Series Showing Pregnancy

lrc Property of:

LEARNING RESOURCES CENTER
Bio-Information Center
28th & Burt
Omaha, Ne. 68178

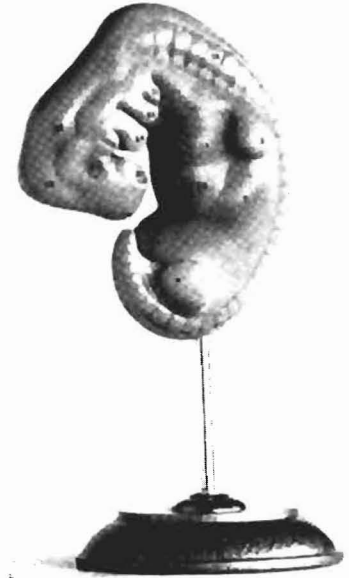



MS 11, MS 14

Embryo

Approximately 4 weeks old.
Enlarged approx. 25 times.
On a stand with base.



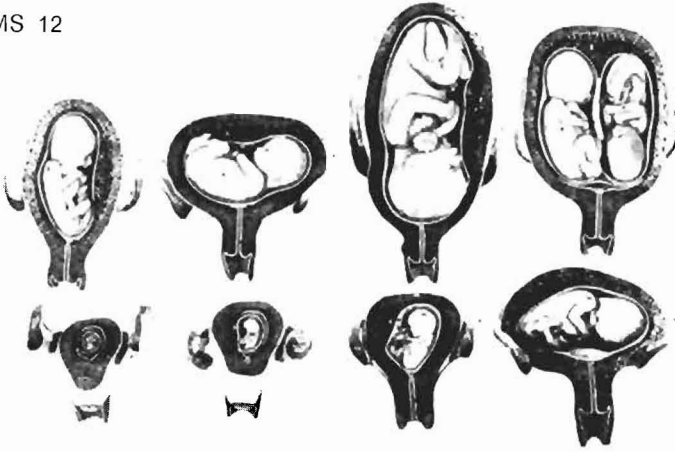
MS 11

1. a. |
1. b. | Primordium of brain
1. c. |
2. | Primordium of nose
3. | Primordium of eye
4. | Primordium of lower jaw
5. a. |
5. b. | Branchial arch
5. c. |
6. a. |
6. b. | Primordium of heart
7. | Primordium of liver
8. | Upper limb buds
9. | Lower limb buds
10. | Primordium of vertebra



MS 12, MS 12/1-8, MS 14

MS 12



Series Showing Pregnancy

Eight Models Showing the Uterus with Embryo and Fetus
in Various Stages of Pregnancy.

**MS 12/1: Uterus with Embryo in first month, umbilical vesicle,
Vesicula umbilicalis, visible.**

1. **Uterus (Womb)**
2. **Placenta (After birth)**
3. **Umbilical cord, Funiculus umbilicalis**
4. **Neck of the uterus, Cervix uteri, with external os of uterus,
Ostium uteri**
5. **Vagina, Vagina**
6. **Oviduct (Fallopian tube), Tuba uterina**
7. **End of tube, with finger-shaped fringes, Fimbriae tubae**

8. **Ovary, Ovarium**
9. **Broad ligament of the uterus, Lig. latum uteri**
10. **Embryo**
11. **Egg-membranes, Membrana decidua, Chorion and Amnion**
12. **Inner wall of the opened amniotic sac, Amnion**
13. **Uterine cavity, Cavum uteri**

MS 12/2: Uterus with embryo in second month, same as model

MS 12/1, but

- 5 : - **Sectional edge of the vagina which has been removed.**

MS 12/3: Uterus with embryo in third month, same as model

MS 12/1, but

- 4 **Neck of the uterus, Cervix uteri, with cervical canal, as well as external and internal os of uterus.**

MS 12/4: Fetus in fourth to fifth month, in prone position

MS 12/5: Fetus in fifth month, breech presentation

MS 12/6: Fetus in fifth month, dorsal position

MS 12/7: Fetus in seventh month, in normal position, placenta with umbilical cord visible.

1. **Uterus (Womb)**
2. **Placenta (After birth)**
 - a **Fetal part**
 - b **Maternal part**
3. **Umbilical cord, Funiculus umbilicalis, with vessels**
4. **Neck of the uterus, Cervix uteri, with external os of uterus, Ostium uteri**
5. **Sectional edge of the vagina, Vagina**
6. **Oviduct (Fallopian tube), Tuba uterina**
7. **End of tube with fringes**
8. **Ovary, Ovarium**
9. **Amniotic sac, Amnion, opened**

MS 12/8: Uterus with twin fetus in the fifth month, in normal position; Models II to IX of the pregnancy series MS 14



MS 13, MS 13/1, MS 14

Pelvis in Median Section with Uterus in Ninth Month of Pregnancy

natural size; in SOMSO-PLAST. Fetus removable.
After Prof. Dr. Petry, Anatomical Institute, Marburg.
On a base.

- 1. Uterus, (Womb)**
- 2. Placenta, (After-birth)**
- 3. Umbilical cord, Funiculus umbilicalis**
- 4. Neck of the uterus, Cervix uteri, with external os of uterus, Ostium uteri**
- 5. Vagina, Vagina**
- 6. Urethra, Urethra feminina**
- 7. Urinary bladder, Vesica urinaria**
- 8. Clitoris, Clitoris**
- 9. Labium minus pudendi**
- 10. Labium majus pudendi**
- 11. Pubic symphysis, Symphysis pubica**
- 12a Sphincter ani internus, M. sphincter ani internus**
- 12b Sphincter ani externus, M. sphincter ani externus**
- 13. Rectum, Rectum**

14. **Last intervertebral disc between lumbar vertebra and sacrum (sacral promontory). The line from here to the posterior edge of the pubic symphysis constitutes the border between the large and the small pelvis.**
15. **Abdominal aorta, Aorta abdominalis**
16. **Inferior vena cava, Vena cava inferior**
17. **Right Kidney, Ren dexter, cut horizontally**
18. **a, b, c, Muscles of the back**
19. **a, b, c, Oblique and transverse abdominal muscles**
20. **Rectus abdominis muscle, M. rectus abdominis**
21. **Spinal cord, Medulla spinalis, in the vertebral canal**

SOMSO models are copyrighted.

Copies, reproductions and facsimiles thereof are prohibited by law.
The reproduction, duplication or translation of this brochure, or any
part thereof, is not permitted.