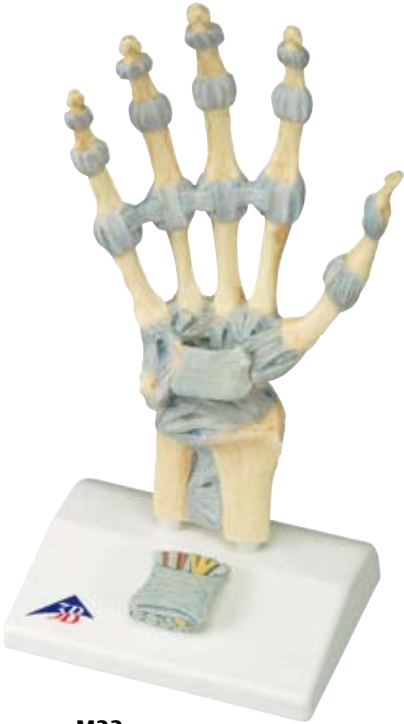
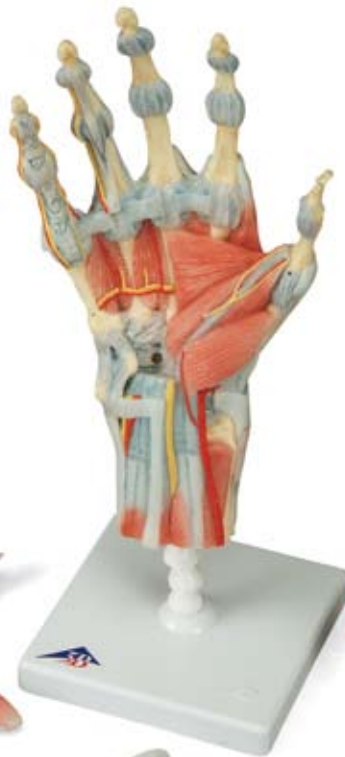


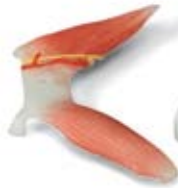...going one step further



M33



M33/1



M33
M33/1

- 1 Ligg. carpometacarpalia palmaria
- 2 Tuberculum ossis trapezii
- 3 Ossa metacarpalia [I-V]
- 4 Processus styloideus radii
- 5 Lig. radiocarpale palmare
- 6 Radius
- 7 Lig. radioulnare palmare
- 8 Ulna
- 9 Lig. ulnocarpale palmare
- 10 Tendo musculi flexoris carpi ulnaris
- 11 Os pisiforme
- 12 Hamulus ossis hamati
- 13 Lig. carpi radiatum
- 14 Ligg. metacarpalia palmaria
- 15 Lig. pisometacarpale
- 16 Lig. pisohamatum
- 17 Ligg. palmaria
- 18 Phalanx distalis
- 19 Phalanx proximalis
- 20 Retinaculum musculorum flexorum
- 21 Membrana interossea antebrachii
- 22 Articulatio metacarpophalangeae,
Ligg. collateralia
- 23 Lig. metacarpale transversum profundum
- 24 Phalanx media
- 25 Articulatio interphalangeae proximalis
- 26 Articulatio interphalangeae distalis
- 27 Articulatio interphalangeae distalis,
Ligg. collateralia
- 28 Articulatio interphalangeae proximalis,
Ligg. collateralia
- 29 Ligg. metacarpalia dorsalia
- 30 Os hamatum
- 31 Os triquetrum
- 32 Lig. collaterale carpi ulnare
- 33 Lig. radiocarpale dorsale
- 34 Lig. radioulnare dorsale
- 35 Tuberculum dorsale radii
- 36 Lig. collaterale carpi radiale
- 37 Ligg. intercarpalia dorsalia
- 38 Ligg. carpometacarpalia dorsalia
- 39 Tendines musculi flexoris digitorum profundi
- 40 Tendo musculi flexoris pollicis longi
- 41 Tendo musculi flexoris carpi radialis
- 42 Nn. digitales palmares communes
- 43 N. medianus
- 44 Mm. lumbricales
- 45 Tendines musculi flexoris digitorum
superficialis
- 46 Aa. digitales dorsales
- 47 Nn. dorsales digitales
- 48 Connexus intertendinei
- 49 Tendines musculi extensorum digitorum
- 50 M. abductor digiti minimi
- 51 Rete carpale dorsale
- 52 R. dorsalis nervi ulnaris
- 53 Retinaculum musculorum extensorum
- 54 R. superficialis nervi radialis
- 55 A. radialis
- 56 Tendo musculi extensoris pollicis brevis
- 57 Tendo musculi extensoris pollicis longus
- 58 Mm. interossei dorsales
- 59 Fasciculi transversi
- 60 M. flexor pollicis brevis
- 61 M. abductor pollicis brevis
- 62 Aponeurosis palmaris
- 63 M. pronator quadratus
- 64 Tendo musculi palmaris longi
- 65 N. ulnaris
- 66 A. ulnaris
- 67 Lig. carpi palmare
- 68 M. palmaris brevis
- 69 Aa. digitales palmares communes
- 70 Pars cruciformis vaginae fibrosae
digitorum manus
- 71 Nn. digitales palmares proprii
- 72 Aa. digitales palmares proprii
- 73 Pars annularis vaginae fibrosae digitorum
manus
- 74 Tendo musculi flexoris digitorum superficialis
- 75 Tendo musculi flexoris digitorum profundi
- 76 M. opponens pollicis
- 77 Arcus palmaris superficialis
- 78 M. flexor digiti minimi brevis
- 79 R. palmaris superficialis arteriae radialis
- 80 Vagina communis tendinum musculorum
flexorum
- 81 M. adductor pollicis
- 82 Vagina tendinis musculi flexoris pollicis longi
- 83 Arcus palmaris profundus
- 84 R. profundus nervi ulnaris
- 85 Mm. interossei palmares

M33

M33/1

English


M33 - Hand Skeleton Model with Ligaments and Carpal Tunnel

This 3 part hand skeleton model shows the anatomical detail of the ligaments and tendons found in the hand, wrist, and lower forearm. The interosseous membrane between the radius and ulna is shown along with the bones of the hand. The flexor retinaculum is removable from the hand skeleton. In addition there is a removable portion that can be fitted on the back of the hand model. This portion features the clinically important structures of the carpal tunnel such as the flexor retinaculum, median nerve, and tendons of the hand.

M33/1 - Hand Skeleton Model with Ligaments and Muscles

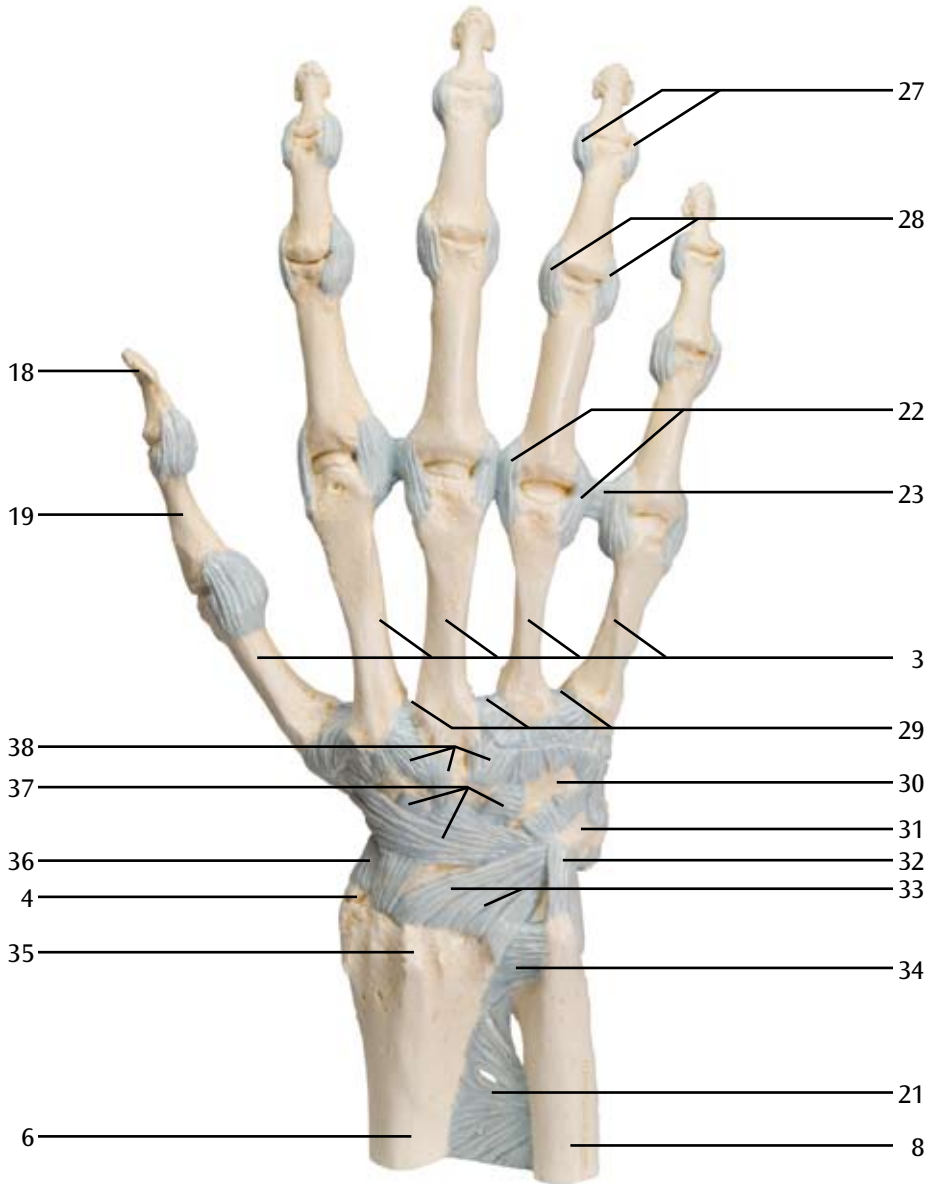
The bones, muscles, tendons, ligaments, nerves, arteries, and veins are all featured in this high quality 4 part model of the hand and lower forearm. The dorsal side of the hand shows the extensor muscles as well as portions of the tendons at the wrist as they pass under the extensor retinaculum. The palmar face of the hand is represented in three layers, the first two removable to allow detailed study of the deeper anatomical layer of the hand. In addition clinically important structures such as the median nerve and superficial palmar arterial arch can be explored in detail in the hand model. The deepest anatomical layer allows for study of the intrinsic muscles and deep palmar arterial arch in addition to other details of the anatomy of the hand.

- A Ligaments of the right hand, dorsal view
 - B Ligaments of the right hand, palmar view
 - C Carpal tunnel region of the right hand, palmar view
 - D Carpal tunnel insert, oblique view from the direction of the fingertips
 - E Ligaments of the right wrist, palmar view
 - F Dorsum of hand (dorsum manus) and extensor side of fingers of right hand
 - G Right palm of the hand (palma manus) with palmar aponeurosis
 - H Right palm of the hand (palma manus) without fasciae and palmar aponeurosis
 - I Superficial palmar arch of the right hand. Fasciae, palmar aponeurosis and flexor retinaculum have been removed.
 - J Deep palmar arterial arch of the right hand
-
- | | |
|--|---|
| 1 Palmar carpometacarpal ligaments | 18 Distal phalanx |
| 2 Tuberculum of trapezium bone | 19 Proximal phalanx |
| 3 Metacarpal bones I-V | 20 Flexor retinaculum |
| 4 Styloid process of radius | 21 Interosseous membrane of forearm |
| 5 Palmar radiocarpal ligament | 22 Metacarpophalangeal joint, collateral ligaments |
| 6 Radius | 23 Deep transverse metacarpal ligament |
| 7 Palmar radioulnar ligament | 24 Middle phalanx |
| 8 Ulna | 25 Proximal interphalangeal joint |
| 9 Palmar ulnocarpal ligament | 26 Distal interphalangeal joint |
| 10 Tendon of flexor carpi ulnaris muscle | 27 Distal interphalangeal joint, collateral ligaments |
| 11 Pisiform bone | 28 Proximal interphalangeal joint, collateral ligaments |
| 12 Hook of hamate bone | 29 Dorsal metacarpal ligaments |
| 13 Radiate carpal ligament | 30 Hamate bone |
| 14 Palmar metacarpal ligaments | 31 Triquetrum bone |
| 15 Pisometacarpal ligament | |
| 16 Pisohamate ligament | |
| 17 Palmar ligaments | |

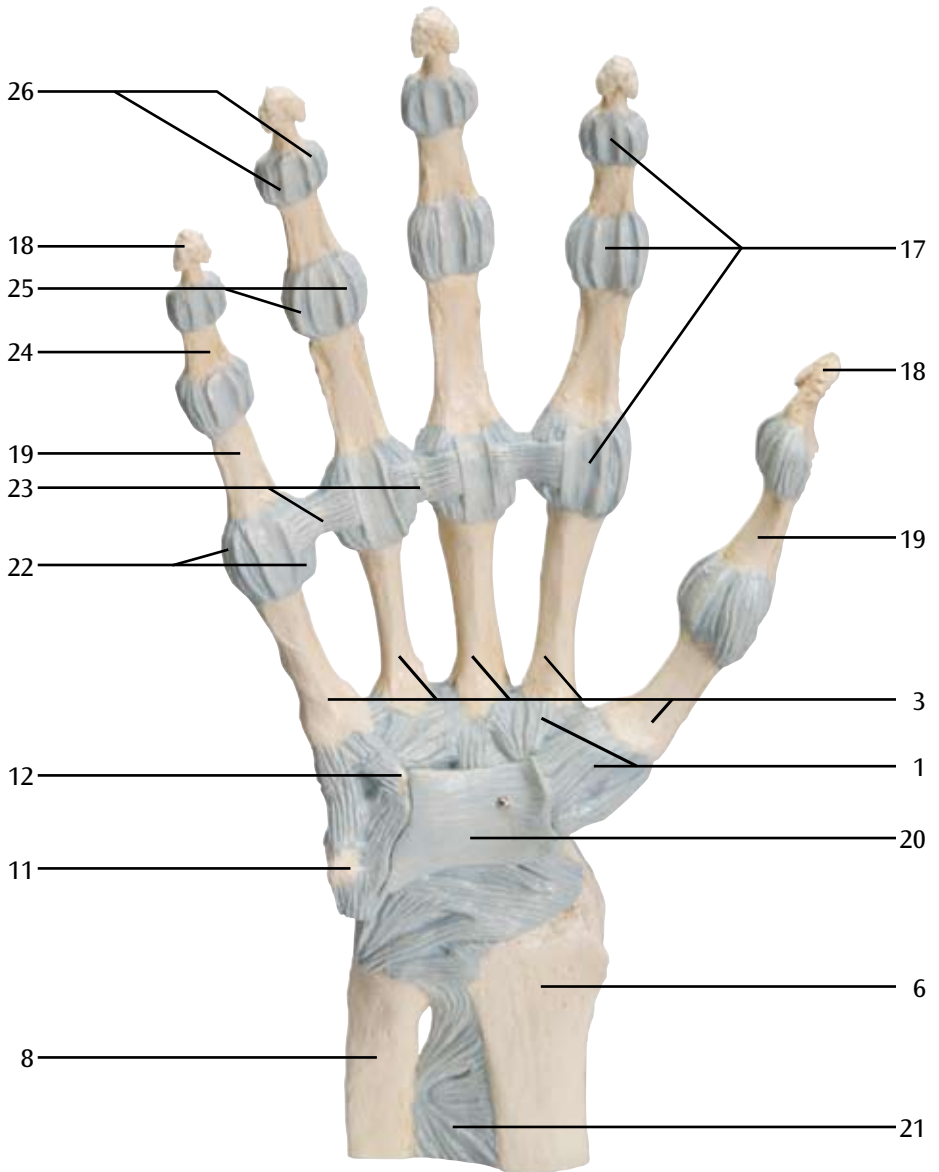
- 
- 32 Ulnar carpal collateral ligament
33 Dorsal radiocarpal ligament
34 Dorsal radioulnar ligament
35 Dorsal tubercle of radius
36 Radial carpal collateral ligament
37 Dorsal intercarpal ligaments
38 Dorsal carpometacarpal ligaments
39 Tendons of deep flexor muscle of fingers
40 Tendon of long flexor muscle of thumb
41 Tendon of radial flexor muscle of wrist
42 Common palmar digital nerves
43 Median nerve
44 Lumbrical muscles
45 Tendons of the superficial flexor muscle of fingers
46 Dorsal digital arteries
47 Dorsal digital nerves
48 Intertendinous connections
49 Tendons of extensor muscle of fingers
50 Abductor muscle of little finger
51 Dorsal carpal arterial arch
52 Dorsal branch of ulnar nerve
53 Extensor retinaculum
54 Superficial branch of radial nerve
55 Radial artery
56 Tendon of short extensor muscle of thumb
57 Tendon of long extensor muscle of thumb
58 Dorsal interosseous muscles
59 Transverse fasciculi of palmar aponeurosis
60 Short flexor muscle of thumb
61 Short abductor muscle of thumb
62 Palmar aponeurosis
63 Pronator quadratus muscle
64 Tendon of palmaris longus muscle
65 Ulnar nerve
66 Ulnar artery
67 Palmar carpal ligament
68 Short palmar muscle
69 Common palmar digital arteries
70 Cruciform part of fibrous digital sheath
71 Proper palmar digital nerves
72 Proper palmar digital arteries
73 Annular part of fibrous digital sheath
74 Tendon of superficial flexor muscle of fingers
75 Tendon of deep flexor muscle of fingers
76 Opposer muscle of thumb
77 Superficial palmar arterial arch
78 Short flexor muscle of little finger
79 Superficial palmar branch of radial artery
80 Common flexor sheath
81 Adductor muscle of thumb
82 Tendinous sheath of long flexor muscle of thumb
83 Deep palmar arterial arch
84 Deep branch of ulnar nerve
85 Palmar interosseous muscles

M33

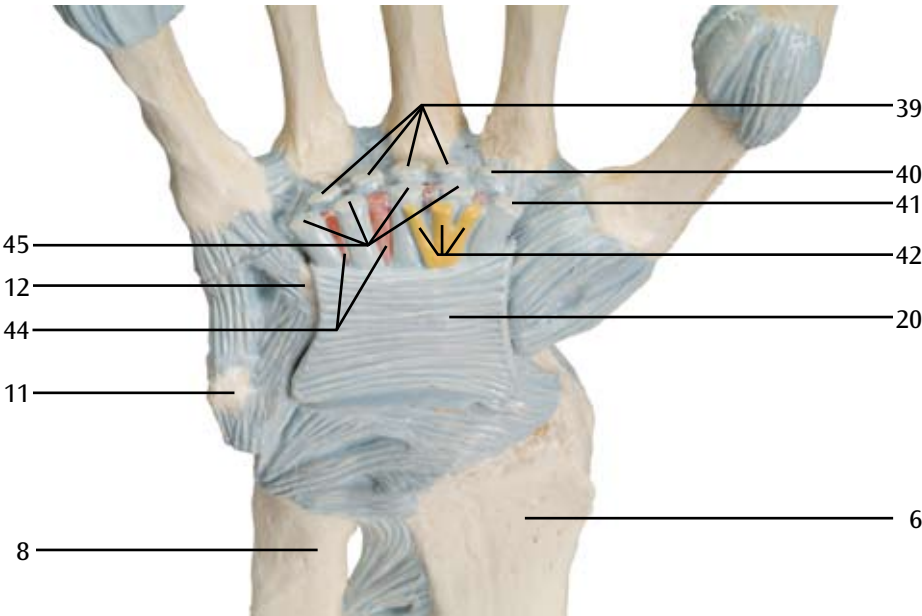
A




M33 B



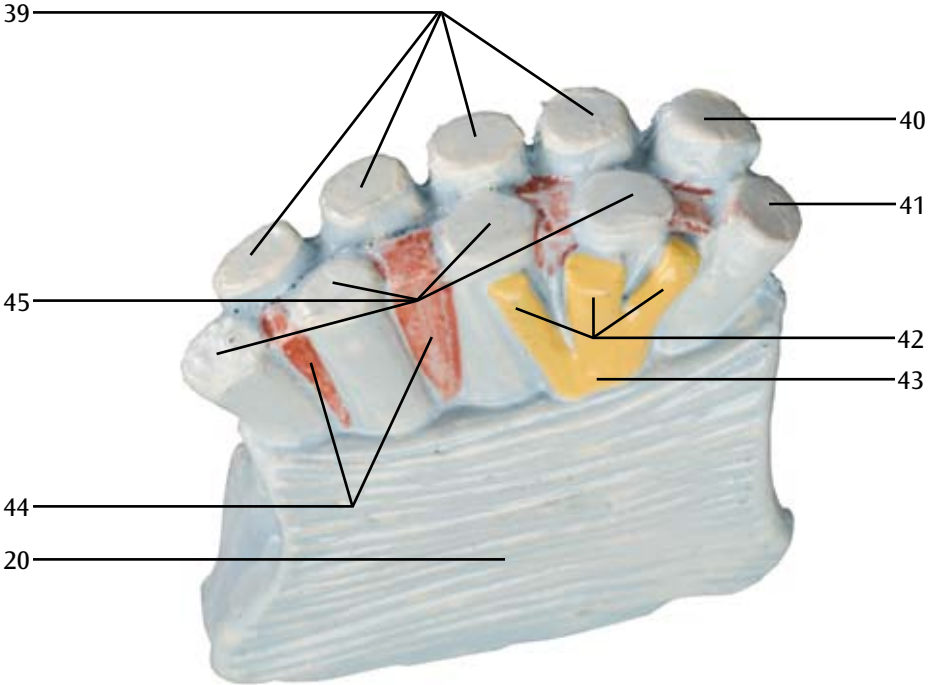
M33
C

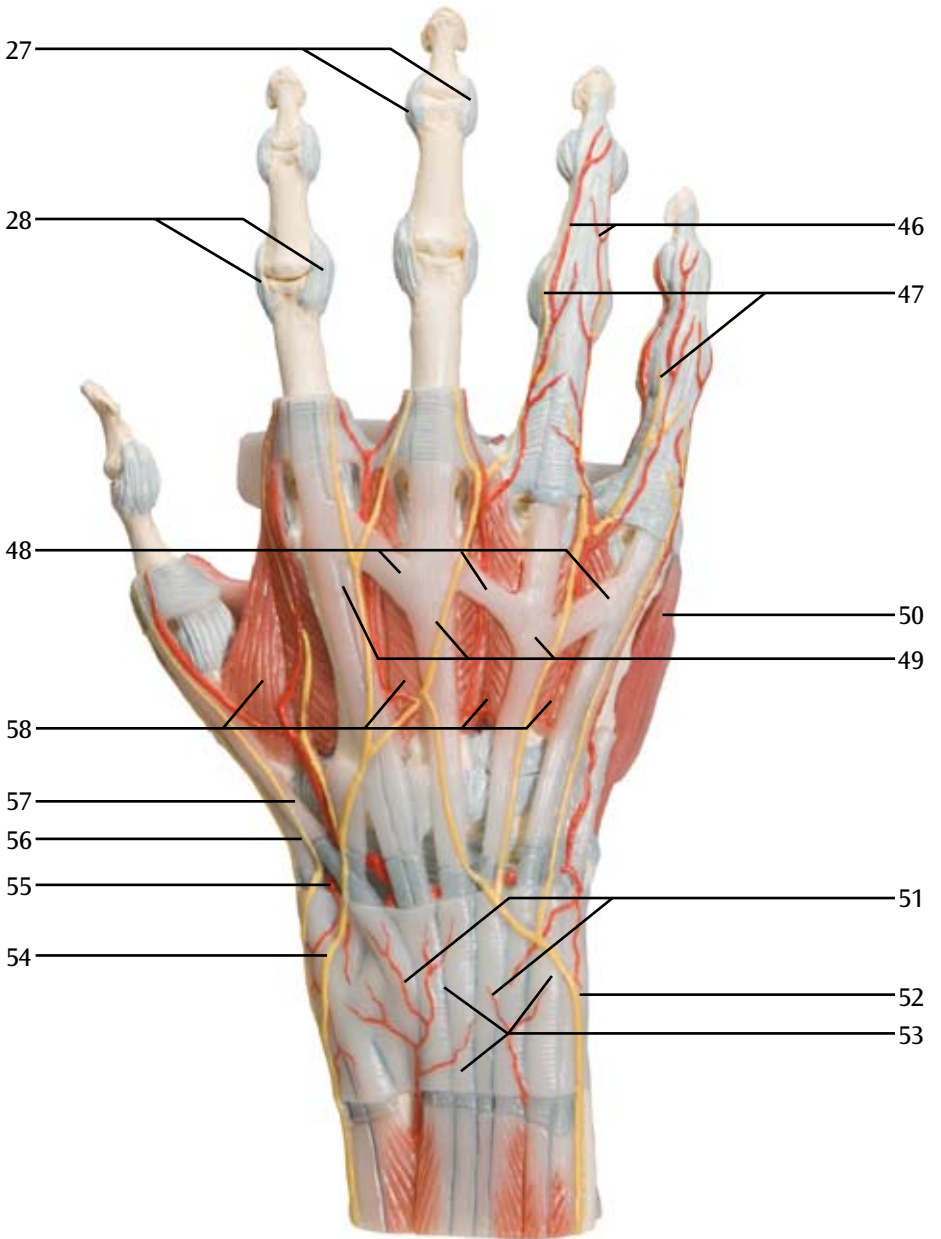


M33
D



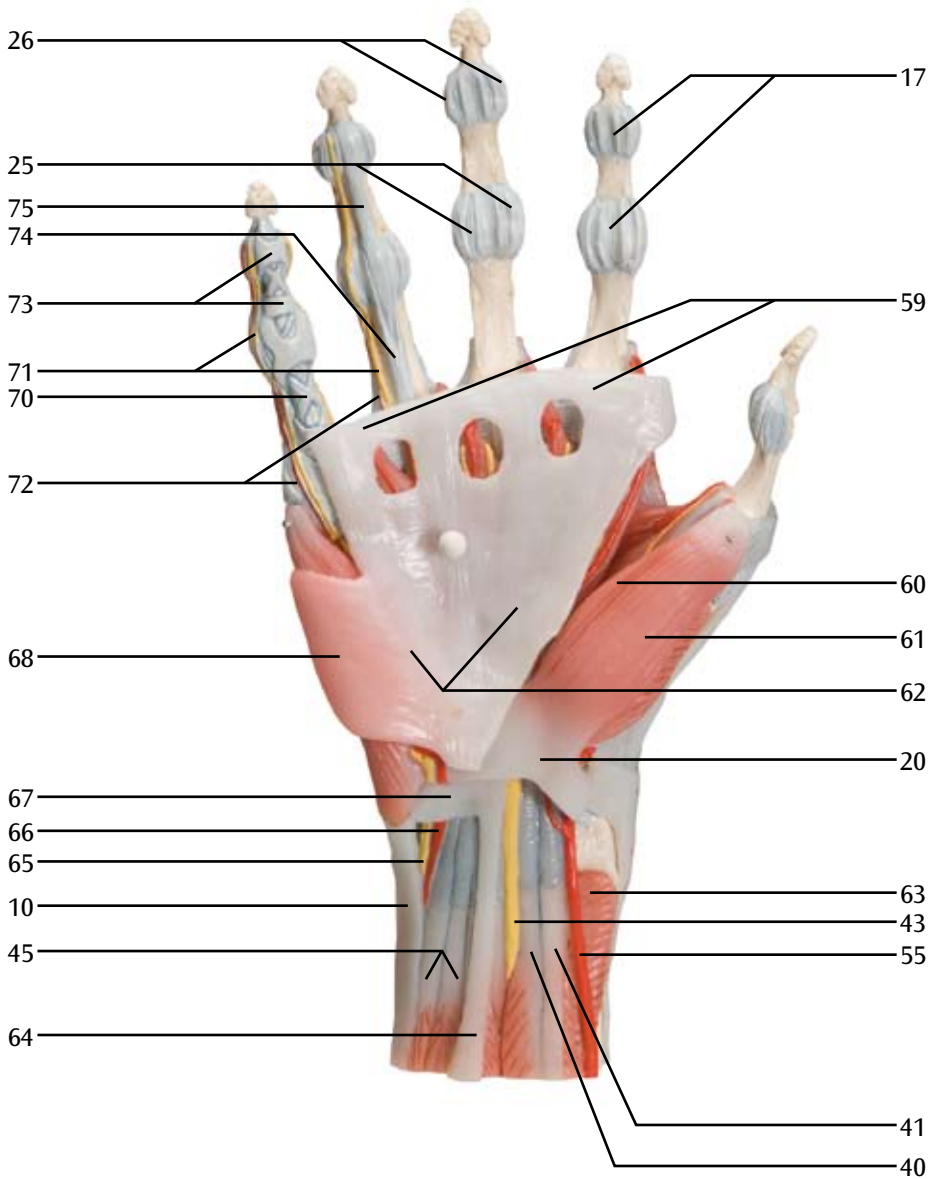
M33
E

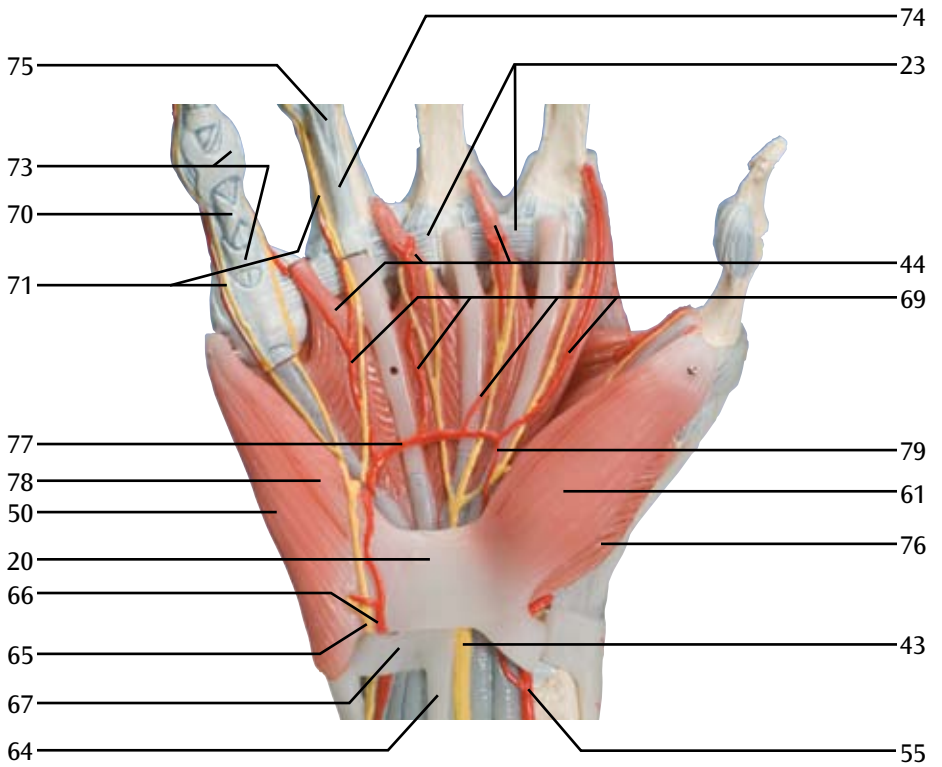




M33/1

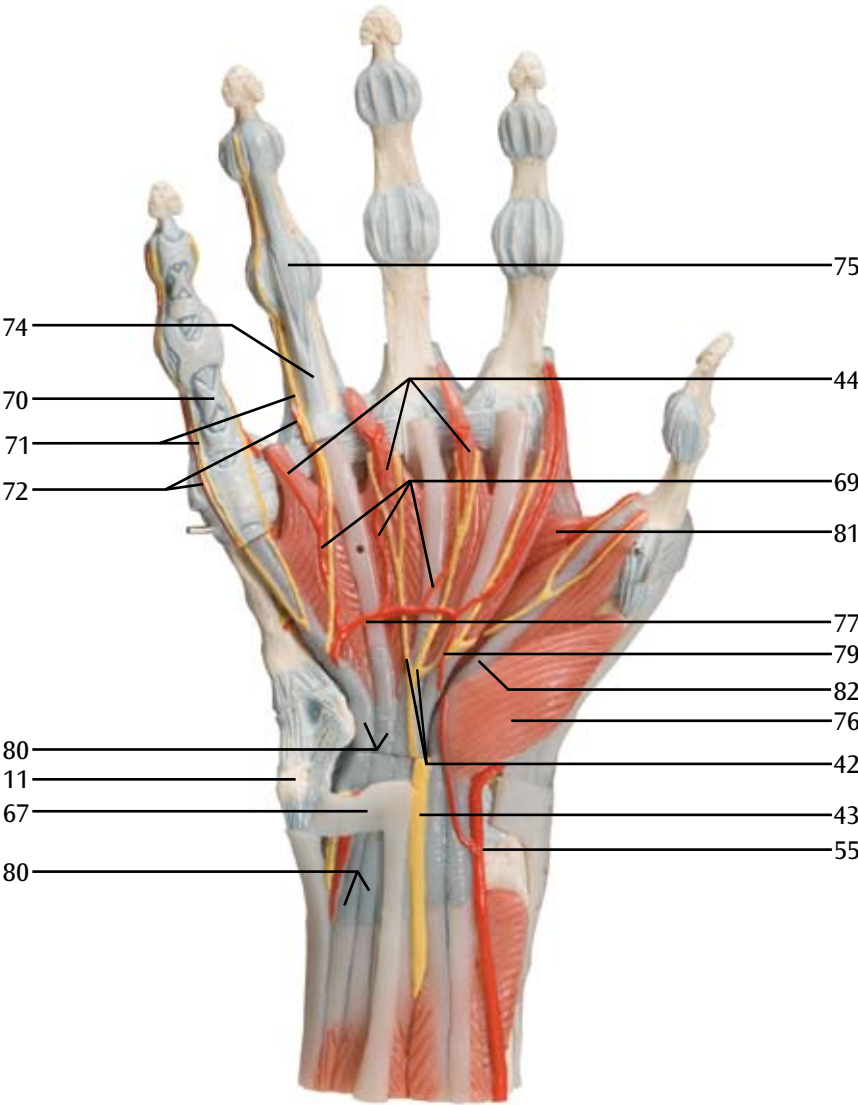
G

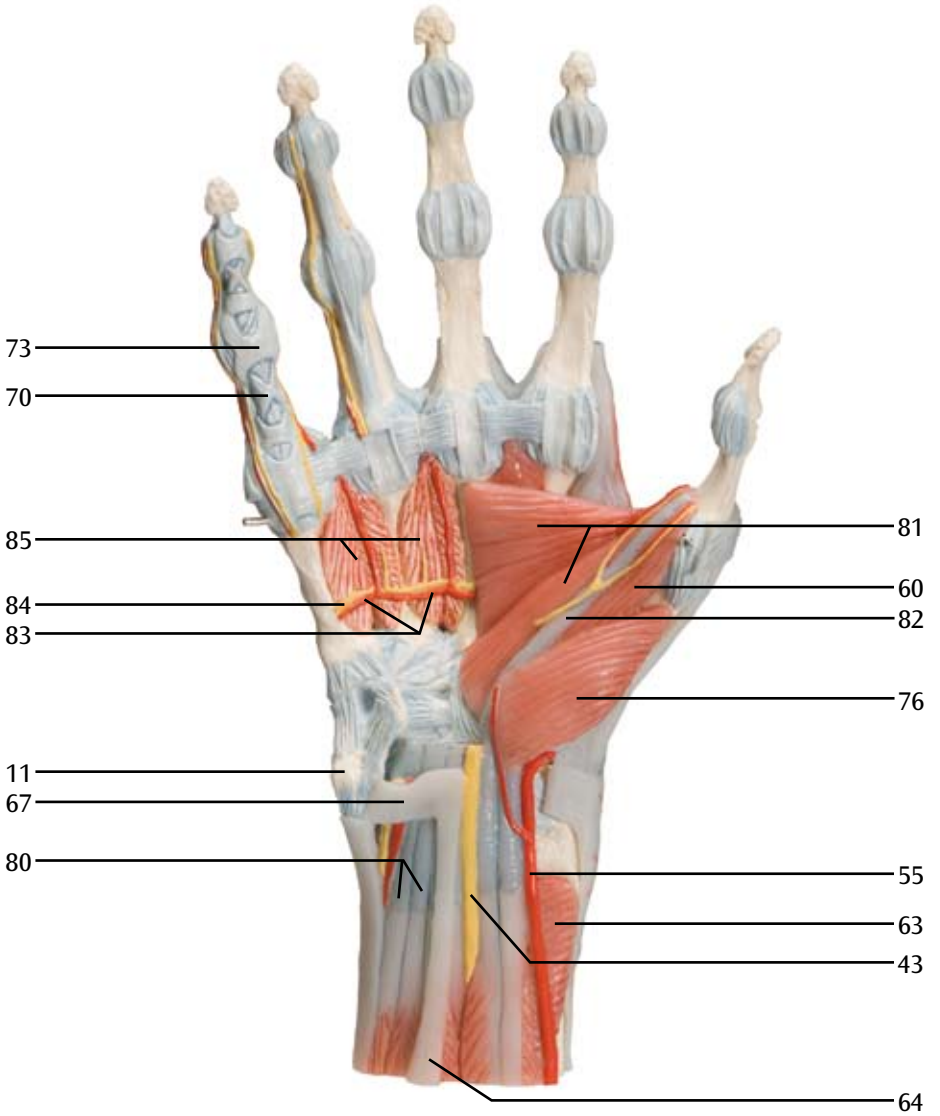




M33/1

I







3B SCIENTIFIC® PRODUCTS

3B Scientific GmbH

Rudorffweg 8 • 21031 Hamburg • Germany

Tel.: + 49-40-73966-0 • Fax: + 49-40-73966-100

www.3bscientific.com • 3b@3bscientific.com

© Copyright 2008 for instruction manual and design of product:
3B Scientific GmbH, Germany